

Jornal Vascular Brasileiro



Este é um artigo publicado em acesso aberto (Open Access) sob a licença Creative Commons Attribution, que permite uso, distribuição e reprodução em qualquer meio, sem restrições desde que o trabalho original seja corretamente citado. Fonte:

[http://www.scielo.br/scielo.php?script=sci\\_arttext&pid=S1677-](http://www.scielo.br/scielo.php?script=sci_arttext&pid=S1677-54492015000300258&lng=en&nrm=iso&tlng=pt&ORIGINALLANG=pt)

[54492015000300258&lng=en&nrm=iso&tlng=pt&ORIGINALLANG=pt](http://www.scielo.br/scielo.php?script=sci_arttext&pid=S1677-54492015000300258&lng=en&nrm=iso&tlng=pt&ORIGINALLANG=pt). Acesso em: 29 mar. 2018.

#### REFERÊNCIA

COELHO NETO, Felipe; KESSLER, Iruena Moraes; ARAÚJO, Gilson Roberto de. Arteriovenous fistula after ultrasound guided foam sclerotherapy: case report. **Jornal Vascular Brasileiro**, Porto Alegre, v. 14, n. 3, p. 258-261, jul./set. 2015. Disponível em: <[http://www.scielo.br/scielo.php?script=sci\\_arttext&pid=S1677-54492015000300258&lng=en&nrm=iso](http://www.scielo.br/scielo.php?script=sci_arttext&pid=S1677-54492015000300258&lng=en&nrm=iso)>. Acesso em: 29 mar. 2018. doi: <http://dx.doi.org/10.1590/1677-5449.0076>.

## Arteriovenous fistula after ultrasound guided foam sclerotherapy: case report

### *Fístula arteriovenosa após escleroterapia com espuma guiada por ultrassom: relato de caso*

Felipe Coelho Neto<sup>1,2</sup>, Iruena Moraes Kessler<sup>1</sup>, Gilson Roberto de Araújo<sup>2</sup>

#### Abstract

Ultrasound-guided foam sclerotherapy has become widespread in the treatment of chronic venous insufficiency secondary to varicose veins. It is a low-cost, outpatient procedure that does not require medical leave. It has demonstrated good clinical results, especially in the more advanced stages of the disease. When employed correctly, it results in low rates of major complications. However, the technique exhibits high recanalization rates over mid and long-term follow up. Additionally, the recanalization mechanism has not yet been explained. This article describes an arteriovenous fistula in a recanalized segment of great saphenous vein previously treated with ultrasound-guided foam sclerotherapy that was detected during post-procedure follow-up with ultrasound.

**Keywords:** varicose veins; arteriovenous fistula; sclerotherapy; sclerosing solutions; surgery; ultrasonography interventional.

#### Resumo

A escleroterapia com espuma guiada por ultrassom tem ganhado espaço no tratamento da insuficiência venosa crônica secundária a varizes dos membros inferiores. Trata-se de procedimento ambulatorial, de baixo custo e sem necessidade de afastamento das atividades habituais. Apresenta bons resultados clínicos, especialmente nos estágios mais avançados da doença. Quando bem aplicada, apresenta baixas taxas de complicações maiores. Porém, a técnica apresenta altas taxas de recanalização no médio e longo prazo, e seu mecanismo ainda não é totalmente compreendido. O presente artigo descreve um caso de fístula arteriovenosa em segmento de recanalização de veia safena magna, após escleroterapia com espuma guiada por ultrassom, e identificada por exame ultrassonográfico de vigilância pós-procedimento.

**Palavras-chave:** varizes; fístula arteriovenosa; escleroterapia; soluções esclerosantes; cirurgia; ultrassonografia de intervenção.

<sup>1</sup>Universidade de Brasília – UnB, School of Medicine, Brasília, DF, Brazil.

<sup>2</sup>Hospital Regional da Asa Norte, Brasília, DF, Brazil.

Financial support: None.

Conflicts of interest: No conflicts of interest declared concerning the publication of this article.

Submitted: October 15, 2014. Accepted: March 23, 2015.

The study was carried out at Hospital Regional da Asa Norte, Brasília, DF, Brazil.

## INTRODUCTION

Chronic venous insufficiency (CVI) is a common disease in clinical practice and its complications, particularly venous stasis ulcers, cause significant morbidity.<sup>1</sup>

One of the treatment options for CVI is ultrasound guided foam sclerotherapy<sup>2</sup> (USFS). It offers satisfactory results, is easy to perform and does not require hospital admission or an operating theater and is generally performed in outpatients settings.<sup>3</sup> After sclerotherapy, the veins are transformed into fibrous cords in a process known as sclerosis.<sup>3</sup> However, medium and long-term recanalization rates are still high.<sup>4</sup>

This article describes a case in which an arteriovenous fistula was identified with ultrasonography in a recanalized segment of the great saphenous vein that had been treated using ultrasound guided foam sclerotherapy.

## CASE DESCRIPTION

An 80-year-old female, white-skinned patient with varicose veins in the lower limbs and a history of arterial hypertension and a mood disorder, complained of pain, feeling of heaviness, tiredness, edema during the afternoon and “darkening” of the distal third of the left leg. Physical examination revealed incipient ochrodermatitis of the ankle and distal third of the left leg and large caliber varicose veins. Arterial clinical examination of the lower limbs revealed no abnormalities. Color Doppler venous ultrasonography ruled out reflux or thrombi in the deep vein system and identified reflux at the left saphenofemoral junction and in the left great saphenous vein, transferring the reflux into medium and large caliber varicose veins along the medial and lateral surfaces of the leg.

The decision was taken to treat the great saphenous vein trunk reflux and the varicose veins using USFS. Polidocanol at 3% was mixed with room air at a proportion of 1:4 to create foam, as described by Tessari et al.<sup>5</sup> Three ultrasound guided punctures were performed with no. 23 needles, two into the great saphenous vein in the thigh and one into a varicose tributary, and a total volume of 10 ml of foam was injected. After the injection, the limb was maintained as immobile as possible, without elevation and without compression of the saphenofemoral junction, as recommended by the European Guidelines for Sclerotherapy in Chronic Venous Disorders.<sup>6</sup> After 5 minutes in this position, 20-30 mmHg elastic stockings were put on and worn continuously for 1 week, removing them only when performing personal hygiene. The patient was encouraged to walk and to engage in daily activities

without restrictions. She was also instructed to wear the stockings during the daytime only from 7 days after the procedure onwards.

No intercurrent conditions occurred during the procedure and the great saphenous vein, and a proportion of its tributaries, were successfully obliterated after a single session. Control ultrasonography at 7, 30 and 90 days did not detect any flow in the great saphenous vein, from the superficial epigastric vein to the point of drainage into the varicose tributaries in the leg. Clinically, there was remission of symptoms and partial resolution of the ochrodermatitis.

Control ultrasonography examination at 6 months showed recanalization of a segment of the great saphenous vein starting at the mid third of the thigh. There was a continuous, ascending and pulsating flow that was not influenced by respiratory rhythm, the Valsalva maneuver or distal compression. Spectral analysis showed that there was low-resistance arterial flow in the venous lumen on a longitudinal scan, compatible with an arteriovenous fistula (AVF), characterized by a high diastolic flow rate and low resistance index (Figure 1). In segments below the AVF, the great saphenous vein was incompressible and had no luminal flow. It was possible to identify the point at which the pulsating flow in the vein lumen originated on both longitudinal and transversal scans (Figures 2 and 3). In view of the fact that the patient remained asymptomatic, it was decided to adopt a policy of watchful waiting. Clinical and ultrasonography findings remained unaltered 12 months after treatment and so six-monthly follow-up and conservative treatment were prescribed.

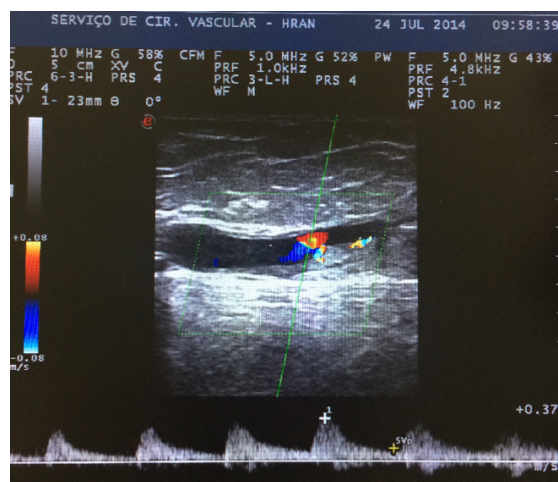


Figure 1. Spectral analysis of luminal flow characterized by high diastolic flow rate and low resistance index, compatible with arteriovenous fistula (AVF).

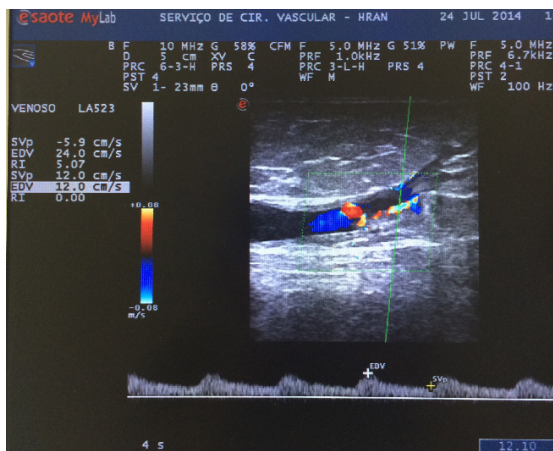


Figure 2. Point of origin of pulsating flow within the saphenous vein lumen.

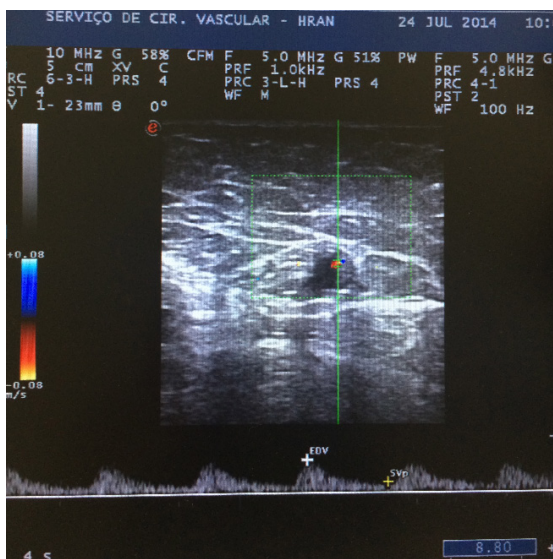


Figure 3. Spectral analysis of transverse scan of saphenous vein.

varying from 10 to 28% have been observed over varying follow-up periods<sup>14</sup> and rates higher than 50% have been observed in studies with the longest follow-up periods.<sup>4</sup> When used appropriately, this is a technique that has low rates of complications<sup>15,16</sup> and AVF is not a normal complication of the procedure. Cavezzi and Parsi<sup>17</sup> have provided a general panorama of the primary complications of USFS. Severe complications such as anaphylactic shock are described as rarities and deep venous thrombosis was reported in 1-3% of cases. The same authors state that there are 13 cases of cerebral vascular accident associated with USFS described in publications since 1994. Reported incidences of minor complications, such as thrombophlebitis, edema and neurological damage, are 4.4%, 0.5% and 0.2%, respectively. Esthetic complications such as ‘matting’ (15-24%) and pigmentation (10-30%) are more frequent.

Jia et al.<sup>18</sup> conducted a large-scale systematic review covering 9,000 patients and did not list AVF among the complications of USFS.

However, when other minimally invasive techniques are also considered, such as endovenous laser and radiofrequency ablation, for example, cases of AVF are described in the literature as possible physiological mechanism of recanalization.<sup>19</sup> There are also reports of recanalization of thrombi with no apparent cause in the superficial or deep vein systems, with inflammation and neovascularization, causing AVFs.<sup>20,21</sup>

When AVF is seen in venous thrombosis with no apparent cause in veins previously subjected to ablative treatments, the suspicion is that they were not effectively treated and that thrombosis was induced in the segments treated.<sup>20</sup> Future studies employing animal models and histopathology could aid in understanding the role of fistulae.

There are no descriptions in the English-language medical literature of an AVF found by ultrasonography after treatment of saphenous vein trunk reflux using USFS. This case description appears to add weight to data reported in publications in the literature on recanalization, in which inflammatory and neovascularization mechanisms act in areas of induced thrombi, rather than in effectively treated veins.<sup>18</sup>

New techniques have brought with them unexpected post-procedural complications that were not described in relation to the classic vein stripping technique. This case report highlights the need for constant ultrasonographic monitoring of minimally invasive treatments, both for early detection of recanalization and in order to document findings that will contribute to better understanding of the long-term behavior of these treatment methods.

## DISCUSSION

The “minimally invasive” techniques such as endovenous laser, radio frequency and foam sclerotherapy have gained recognition over the last 15 years to the extent that they now play a primary role in treatment of CVI secondary to varicose veins of the lower limbs. These are outpatient procedures performed with tumescent local anesthesia and do not require hospital admission or medical leave and many studies have demonstrated their safety and efficacy for elimination of venous reflux.<sup>7-10</sup>

Ultrasound-guided foam sclerotherapy produces good clinical results, as has been shown in studies conducted in Brazil by Figueiredo et al.,<sup>11</sup> Silva et al.<sup>2</sup> and Coelho Neto et al.<sup>13</sup> However, recanalization rates



## ■ REFERENCES

- Silva MC. Chronic venous insufficiency of the lower limbs and its socio-economic significance. *Int Angiol.* 1991;10(3):152-7. PMID:1765717.
- Wright D, Gobin JP, Bradbury AW, et al. Varisolve® polidocanol microfoam compared with surgery or sclerotherapy in the management of varicose veins in the presence of trunk vein incompetence: European randomized controlled trial. *Phlebology.* 2006;21(4):180-90. <http://dx.doi.org/10.1258/026835506779115807>.
- Guidelines/Outcomes Committee, Task Force. Guidelines of care for sclerotherapy treatment of varicose and telangiectatic leg veins. *J Am Acad Dermatol.* 1996;34(3):523-8. [http://dx.doi.org/10.1016/S0190-9622\(96\)90467-3](http://dx.doi.org/10.1016/S0190-9622(96)90467-3). PMID:8609276.
- Belcaro G, Cesarone MR, Di Renzo A, et al. Foam-sclerotherapy, surgery, sclerotherapy, and combined treatment for varicose veins: a 10-year, prospective, randomized, controlled, trial (VEDICO trial). *Angiology.* 2003;54(3):307-15. <http://dx.doi.org/10.1177/000331970305400306>. PMID:12785023.
- Tessari L, Cavezzi A, Frullini A. Preliminary experience with a new sclerosing foam in the treatment of varicose veins. *Dermatol Surg.* 2001;27(1):58-60. PMID:11231246.
- Rabe E, Breu FX, Cavezzi A, et al. European guidelines for sclerotherapy in chronic venous disorders. *Phlebology.* 2014;29(6):338-54. <http://dx.doi.org/10.1177/0268355513483280>. PMID:23559590.
- Darwood RJ, Gough MJ. Endovenous laser treatment for uncomplicated varicose veins. *Phlebology.* 2009;24(Supl 1):50-61. <http://dx.doi.org/10.1258/phleb.2009.09s006>. PMID:19307441.
- Gohel MS, Davies AH. Radiofrequency ablation for uncomplicated varicose veins. *Phlebology.* 2009;24(Supl 1):42-9. <http://dx.doi.org/10.1258/phleb.2009.09s005>. PMID:19307440.
- Smith PC. Foam and liquid sclerotherapy for varicose veins. *Phlebology.* 2009;24(Supl 1):62-72. <http://dx.doi.org/10.1258/phleb.2009.09s007>. PMID:19307442.
- Proebstle TM, Vago B, Alm J, Göckeritz O, Lebard C, Pichot O. Treatment of the incompetent great saphenous vein by endovenous radiofrequency powered segmental thermal ablation: first clinical experience. *J Vasc Surg.* 2008;47(1):151-6. <http://dx.doi.org/10.1016/j.jvs.2007.08.056>. PMID:18178468.
- Figueiredo M, Araújo SP, Penha-Silva N. Microfoam ultrasound-guided sclerotherapy in primary trunk varicose veins. *J Vasc Bras.* 2006;5(3):177-83. <http://dx.doi.org/10.1590/S1677-54492006000300005>.
- Silva MAM, Burihan MC, Barros OC, Nasser F, Ingrand JC, Nesar A. Resultados do tratamento da insuficiência venosa crônica grave com espuma de polidocanol guiada por ultrassom. *J Vasc Bras.* 2012;11(3):206-11. <http://dx.doi.org/10.1590/S1677-54492012000300007>.
- Coelho Neto F, Araújo GR, Kessler IM, Amorim RF, Falcão DP. Treatment of severe chronic venous insufficiency with ultrasound-guided foam sclerotherapy: a two-year series in a single center in Brazil. *Phlebology.* 2015;30(2):113-8. <http://dx.doi.org/10.1177/0268355513517225>. PMID: 24335090.
- National Institute for Clinical Excellence [site na Internet]. Interventional procedures overview of ultrasound guided foam sclerotherapy for varicose veins. London: NICE; 2004 [citado 2006 set 26]. <http://guidance.nice.org.uk/download.aspx?o=ip244overview>.
- Guex JJ, Allaert FA, Gillet JL, Chleir F. Immediate and midterm complications of sclerotherapy: report of a prospective multicenter registry of 12,173 sclerotherapy sessions. *Dermatol Surg.* 2005;31(2):123-8, discussion 128. <http://dx.doi.org/10.1097/00042728-200502000-00001>. PMID:15762201.
- Weiss RA, Weiss MA. Incidence of side effects in the treatment of telangiectasias by compression sclerotherapy: hypertonic saline vs. polidocanol. *J Dermatol Surg Oncol.* 1990;16(9):800-4. <http://dx.doi.org/10.1111/j.1524-4725.1990.tb01563.x>. PMID:2398199.
- Cavezzi A, Parsi K. Complications of foam sclerotherapy. *Phlebology.* 2012;27(Supl 1):46-51. <http://dx.doi.org/10.1258/phleb.2012.012S09>. PMID:22312067.
- Jia X, Mowatt G, Burr JM, Cassar K, Cook J, Fraser C. Systematic review of foam sclerotherapy for varicose veins. *Br J Surg.* 2007;94(8):925-36. <http://dx.doi.org/10.1002/bjs.5891>. PMID:17636511.
- Labropoulos N, Bhatti A, Leon L, Borge M, Rodriguez H, Kalman P. Neovascularization after great saphenous vein ablation. *Eur J Vasc Endovasc Surg.* 2006;31(2):219-22. <http://dx.doi.org/10.1016/j.ejvs.2005.06.030>. PMID:16099695.
- Labropoulos N, Bhatti AF, Amaral S, et al. Neovascularization in acute venous thrombosis. *J Vasc Surg.* 2005;42(3):515-8. <http://dx.doi.org/10.1016/j.jvs.2005.05.036>. PMID:16171599.
- Barros FS, Pontes SM, Silva WP, et al. Arteriovenous fistula in deep venous thrombosis identified by color-flow Doppler ultrasonography. *J Vasc Bras.* 2006;5(3):224-8.

### Correspondence

Felipe Coelho Neto  
 Centro Médico Julio Adnet  
 SEPS 709/909, salas 419-422, bloco A  
 CEP 70100-360 - Brasília (DF), Brazil  
 Tel.: +55 (61) 33281940  
 E-mail: contato@drfelipecoelho.com.br

### Author information

FCN – Vascular surgeon at the Vascular Surgery Unit, Hospital Regional da Asa Norte; MSc in Medical Sciences from Universidade de Brasília (UnB).  
 IMK – MSc and a PhD in Medical Sciences from Universidade de Brasília (UnB).  
 GRA – Vascular surgeon at the Vascular Surgery Unit, Hospital Regional da Asa Norte.

### Author contributions

Conception and design: FCN  
 Analysis and interpretation: FCN, GRA  
 Data collection: FCN  
 Writing the article: FCN, IMK  
 Critical revision of the article: FCN, IMK  
 Final approval of the article\*: FCN, GRA, IMK  
 Statistical analysis: N/A  
 Overall responsibility: FCN

\*All authors have read and approved of the final version of the article submitted to *J Vasc Bras.*