

Revista ARS VETERINARIA - Permite-se a reprodução total ou parcial dos trabalhos, desde que seja indicada explicitamente a fonte de referência.

Revista ARS VETERINARIA - It allows the total or partial reproduction of the work, provided the source reference is explicitly indicated.

Fonte:

<http://www.arsveterinaria.org.br/index.php/ars/about/submissions#copyrightNotice> .
Acesso em: 25 jul. 2014

REFERÊNCIA

FONSECA, L. A. et al. Comparative study of splenic puncture and peripheral blood smears for diagnosis of babesiosis in horses. **ARS Veterinaria**, Jaboticabal, v.27, n.4, 211-215, 2011. Disponível em: <

<http://www.arsveterinaria.org.br/index.php/ars/article/viewFile/377/362>>. Acesso em: 27 jul. 2014.

COMPARATIVE STUDY OF SPLENIC PUNCTURE AND PERIPHERAL BLOOD SMEARS FOR DIAGNOSIS OF BABESIOSIS IN HORSES

ESTUDO COMPARATIVO ENTRE ESFREGAÇOS DE PUNÇÃO ESPLÊNICA E DE SANGUE PERIFÉRICO PARA DIAGNÓSTICO DE BABESIOSE EQUINA

L. A. FONSECA¹, A. R. TEIXEIRA NETO², E. F. FONSECA³, A. M. G. B. SILVA⁴,
E. M. M. LIMA², R. F. GODOY^{2*}

SUMMARY

The objective of this work is to compare the efficacy of the splenic puncture and peripheral blood smear techniques to determine a simple and more precise method to diagnose subclinical babesiosis in horses submitted to physical effort or competitions. For this purpose, the splenic puncture and peripheral blood smears of fifteen healthy horses, weighing an average 350 Kg, aged between six to thirteen years, of both genders, without clinical signs of babesiosis and with history of tick infestation were compared. The peripheral blood smear collected from the horses' ear were all negative for babesiosis. However, the splenic puncture blood smear was positive for *Babesia caballi* or *Theileria equi* in five animals. Both methods are little invasive, safe and easy to be performed, but the splenic puncture smear seems to be more effective to detect chronic babesiosis in horses.

KEY-WORDS: Babesiosis. Diagnosis. Peripheral blood smear. Splenic puncture smear.

RESUMO

O objetivo deste trabalho foi o de comparar os resultados obtidos com o uso das técnicas de esfregaço de sangue periférico e de punção esplênica e de verificar uma metodologia simples e precisa para diagnóstico de babesioses em cavalos portadores subclínicos, submetidos ao esforço físico ou competições. Quinze equinos hígidos, sem sinais clínicos de babesiose, com peso médio de 350 Kg, idade entre 6 a 13 anos, de ambos os sexos e com histórico de infestação por carrapatos, foram utilizados. No esfregaço de sangue colhido da orelha, nenhum animal apresentou resultado positivo enquanto que na punção esplênica cinco animais foram positivos para a presença de *Babesia caballi* ou *Theileria equi*. Os dois métodos são de fácil realização, seguros e pouco invasivos, porém o esfregaço da punção esplênica parece ser mais eficaz em detectar casos latentes de babesiose em equinos.

PALAVRAS-CHAVE: Babesiose. Diagnóstico. Esfregaço de sangue periférico. Punção de baço.

¹ Mestranda do Programa de Pós Graduação em Saúde Animal, Faculdade de Agronomia e Medicina Veterinária, Universidade de Brasília (UnB), Brasília, DF.

² Professor Adjunto da Faculdade de Agronomia e Medicina Veterinária, Universidade de Brasília (UnB), Hospital Veterinário de Grandes Animais, Galpão 04, Granja do Torto, Brasília, DF, 70636-200, Brasil. *Autor para correspondência: robertagodoy@unb.br

³ Tenente-Veterinário do Primeiro Regimento de Cavalaria de Guarda, Setor Militar Complementar s/n° 1° Regimento de Cavalaria de Guardas, Brasília, DF.

⁴ Residente do Hospital Veterinário de Grandes Animais, Universidade de Brasília (UnB), Brasília, DF.

INTRODUCTION

Babesiosis or piroplasmosis is an intra-erythrocyte disease that affects mammals. It is a tick-borne infection caused by the protozoa *Babesia* or *Theileria* (ZAUGG, 2002), of great importance in equines, since it is one of the main diseases to affect horses (NIZOLI, 2005). Animals that carry the antibodies against *Babesia*, considered chronic carriers, perform at a lower level compared to the healthy counterpart (SOUZA et al., 2007). Despite the severity of acute illness, it is very important to diagnose the animals with the subclinical disease, such as chronic carriers of the parasite. Parasitemia is often absent in carriers, but can reoccur after immuno-suppression or strenuous exercise, which causes economical losses resulting from under performance, inappetence and weight loss (BOTTEON et al., 2005). These factors demonstrate the importance of developing simple and efficient techniques for the diagnosis of the disease.

When the parasite invades the organism it activates an alternative complement pathway. The red blood cells infected by *Babesia caballi* or *Theileria equi*, incorporate antigens of the parasite in their cell membranes, which leads the antibodies to remove them through the mononuclear phagocyte system (TIZARD, 1998). In cases where the animal shows signs of acute illness but before hemoglobinuria manifests itself, peripheral blood smears can help to detect the presence of the parasite by optical microscopy (BRÜNING, 1996). The peripheral blood may be drawn from the jugular vein or from the vein that carries blood to the ear. During the latent stage of the disease, the parasite is not usually detected in the peripheral blood smears because parasitemia is less than 0.01%, thus increasing the number of false negatives (NIZOLI, 2005).

The spleen has a higher concentration of parasitized blood cells due to its important role in hemocaterese, which explains the use of splenic puncture blood smear to diagnose the infection. The blood is collected directly from the spleen (MOREIRA et al., 2007).

The objective of this study was to compare the results from peripheral blood smear and splenic puncture smear to determine a simple method to diagnose equine babesiosis in animals that do not show the clinical symptoms of the disease.

MATERIAL AND METHODS

Blood was drawn by puncturing the spleen and the internal ear vein of 15 horses weighing an average 350 kg, aged between 6 and 13 years old of both genders. The non-determined breed horses came from the Setor de Apreensão de Secretaria de Agricultura e Pecuária e Abastecimento, in Brasília, DF (SEAPA-DF). Some of these animals were confined in stalls and some were free in the paddocks. Clinical examination showed that these horses did not display any signs indicating that they had babesiosis before or at the moment of blood

sampling. However, all horses had a history of tick infestation.

After cleansing the site, blood was drawn with a 40 x 16 needle from the vein that irrigates the inner side of the atrium. The sample was subsequently transferred to a microscope slide, where the blood smear was prepared according to the technique described by Coles (1984). For this purpose, we used slides for optical microscope and a commercially available extender without indentations and narrower than the slide. Immediately after the blood was drawn, the smear was prepared on a flat surface, with an extender that formed a 30-degree angle with the slide. All slides were properly identified.

Immediately afterwards, the same horses underwent spleen puncture to prepare blood smears according to the technique described by Souza et al. (2007). The spleen puncture (Figure 1) was performed using a 30 x 8 needle coupled with a syringe that contained 10 mL of 0.2% EDTA solution. After shaving and cleaning the site with povidone-iodine, the spleen was punctured on the 17th intercostal space in the left antimere. The needle was fully inserted at a 90-degree angle to reach the spleen, when the blood was then aspirated. After this procedure, the smears were prepared as described above.

The fast stain Panótico was used to stain the slides, which were then left to air-dry. The readings, in zigzag, were conducted in a optical microscope equipped with immersion objective (100x). After identification of the parasite, the specific determination was made according to the morphology. *B. caballi* is longer than 3µm and their merozoites are found in pairs (NIZOLI, 2005) and *T. equi* is longer than 2µm and the merozoites are present in tetrads, in the shape of the Maltese cross (COLE, 1984).

All data were tabulated and the frequency was calculated.

RESULTS AND DISCUSSION

The splenic blood sampling method was safe and easy to perform, the horses did not need to be anesthetized or sedated during the procedure and showed no signs of discomfort or pain. The spleen puncture was not more difficult or costly than the peripheral blood sampling on the ear. The amount of blood collected ranged from 0.4 to 0.8 mL.

Table 1 shows the results of the clinical examinations of the horses before the blood samples were taken, their living environment and the results obtained by splenic puncture. The highest number of positive results came from horses that were kept in the paddocks and had ticks.

The peripheral blood smear technique is important to diagnose parasitic diseases such as *Anaplasma* and *Babesia* in some species (COLES, 1984). This technique allows to determine the prognosis of acute infections and also to obtain information on the associated anemia and erythrocyte morphology.



Figura 1 - Splenic puncture procedure. The 25 x 30 needle is inserted at 90° angle on the 17th intercostal space.

Table 1 - Data of the horses used in the babesiosis study, type of confinement and physical condition at the time of blood sampling, and the blood smear results as well. All animals were negative for the peripheral blood smear.

Animal	Presence of tick	Confinement	Color of Mucosa	T °C	FC (BPM)	FR (MPM)	Splenic blood smear result
1	yes	paddock	Normal	37.5	36	12	Negative
2	no	stall	Normal	36.5	28	12	Negative
3	no	stall	Normal	36.8	36	12	Positive – <i>T. equi</i>
4	no	stall	Normal	36.4	40	12	Negative
5	no	stall	Normal	36.9	36	12	Negative
6	yes	paddock	Normal	37.3	56	20	Positive – <i>T. equi</i>
7	yes	paddock	Normal	37.3	44	20	Negative
8	yes	stall	Normal	37.7	44	10	Negative
9	yes	paddock	Normal	37.2	36	12	Negative
10	yes	paddock	Normal	38.4	32	10	Positive – <i>T. equi</i>
11	no	stall	Normal	37.6	40	12	Positive – <i>B. caballi</i>
12	no	stall	Normal	37.3	48	10	Negative
13	yes	paddock	Normal	37.4	40	10	Negative
14	yes	paddock	Normal	37.5	56	16	Positive – <i>T. equi</i>
15	yes	paddock	pale	38.1	44	12	Positive – <i>T. equi</i>

Reference values: Mucosa: normal colored; Temperature: 37.5-38°C ; FC: 32-44; FR: 8-16 (GÜRTLER et al. 1984).

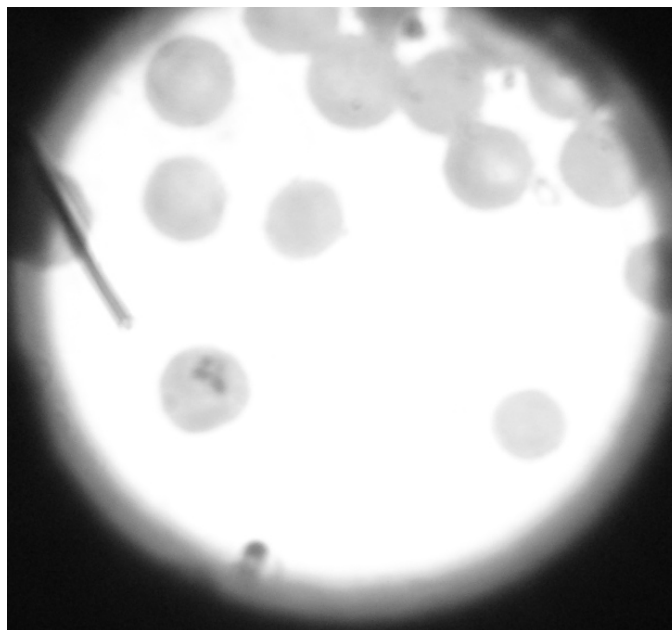


Figure 2 - Blood smear of spleen puncture of horse number 3 showing the presence of *Theileria equi* in a red cell (arrow).

Preferably, the blood smear should be prepared immediately after the blood sample is drawn. According to Brüning (1995), the parasite can be visualized in peripheral blood samples of horses with acute disease, but before hemoglobinuria establishes itself. The peripheral blood sample results were negative for the presence of Babesia.

Theileria equi and *Babesia caballi* are difficult to be visualized in the peripheral blood smear of horses, because they are present in only 1 to 8% of the erythrocytes. *Theileria equi* may appear in the shape of the Maltese cross, forming a tetrad. While *Babesia caballi* is larger than *Theileria equi*, which is less than 2 µm, and *B. Caballi* that measures between 2.5 and 4 µm (COLES, 1984). During disease chronic phase, when the level of parasitemia is less than or equal to 0.01%, the sensitivity of the peripheral blood smear technique decreases increasing the number of false-negatives. All the horses used in this study had no clinical signs of babesiosis and no temperature peaks, which can explain the absence of the parasite from the blood. Therefore, showing another downside of this method, the inability to detect the chronic or latent form of the disease. The results obtained in this study also showed that the sensitivity of the peripheral blood smear is lower compared to splenic puncture blood smear, given that the positive results of the latter were not picked up by the first.

According to the blood samples from the splenic puncture, five out fifteen horses (33.3%) were positive for *Theileria equi* (Figure 2) or *Babesia caballi*, that is, four horses were positive for *Theileria equi* and one for *Babesia caballi* (Table 1).

According to Moreira et al. (2007) the spleen has major role in hemocaterese and therefore has a high number of parasitized red blood cells, for this reason the chances of finding the parasite in splenic blood smears are higher even during the chronic stages of the disease. This quick and minimally invasive method can be easily adopted as a diagnosis test for horses with suspected babesiosis. These observations were confirmed in the screen experiment, since *Babesia* or *Theileria* were detected in animals that did not show any clinical signs of the disease. This diagnosis method is useful to detect chronic stages of the disease; however, false negatives may also occur.

The horse that was positive for *Theileria equi* according to the splenic puncture blood smear result, displayed clinical signs of babesiosis such as, fever peaks and icteric mucous membranes one week after the blood samples were drawn. This fact demonstrates the importance of the splenic blood smear to detect the latent or chronic stages of the disease.

Although parasites were detected in the splenic blood sample of some horses, they were not treated, since this was not the objective of the study and there were no clinical signs of the disease. In addition to the fact that they belonged to carters and were always in contact with the parasite vector and once treated, the antibodies against *Babesia* or *Theileria* could decrease causing the disease to flare up.

The equine babesiosis despite not being a disease with high mortality rate has great impact on the international horse market, mainly because it creates barriers to the movement of seropositive animals to areas where the disease is not endemic in the United States, Canada, Japan and some European countries.

Most of these countries have the vectors of babesiosis and the entry of carrier animals can lead this disease to become endemic. In addition to diagnosis tests, control measures are adopted such as quarantine and tick control to prevent the transmission of babesiosis (NIZOLI, 2005). Brazil, where the disease is endemic, has one of the largest horse herds in the world, but has also superior animal husbandry, and the export of these animals has brought economic gain to the country. Another problem is when animals from non-endemic regions are taken to places where the parasite is present, since these horses can now develop the disease in its acute form and depending on the severity it can lead to death (BALDANI et al., 2004). Animals that take part in international races also suffer from these barriers and should be kept with low antibody titers or parasite free.

In addition to economic losses, according to Nizoli (2005), babesiosis can cause loss of athletic performance of animals since the stress can decrease the antibodies and cause a disease flare-up. The study of the disease and advances in diagnostic techniques allow to reduce the damage that babesiosis can cause and minimize the number of animals that are treated without the presence of the parasite being confirmed. According to Botteon et al. (2005), as a rule, animals whose performance drops are probably undergoing treatment for babesiosis without a final diagnosis. The diagnosis techniques are of utmost importance especially for rapid detection of the parasite and an effective treatment.

It was concluded that both techniques are easy to perform and inexpensive, they can be performed in the field and the carriers are identified quickly. Although, the splenic puncture blood smear displayed a greater detection rate compared to peripheral blood smear, it is not possible to conclude that one method is better than the other because the number of horses used in the study was relatively small; therefore, further research is necessary to determine whether the splenic puncture technique is indeed more precise to diagnose babesiosis in horses.

REFERENCES

BALDANI, C. D.; MACHADO, R. Z.; BOTTEON, P. T. L.; TAKAKURA, F. S.; MASSARD, C. L. An enzyme-linked immunosorbent assay for the detection of IgG antibodies against *Babesia equi* in horses. **Ciência Rural**, v.34, n.5, p.1525-1529, 2004.

BOTTEON, P. T. L.; BOTTEON, R. C. C. M.; REIS, T. P.; MASSARD, C. L. Babesiose em cavalos atletas portadores. **Ciência Rural**, v.35, n.5, p.1136-1140, 2005.

BRÜNING, A. Equine piroplasmosis an update on diagnosis, treatment and prevention. **British Veterinary Journal**, v.152, n.2, p.140-151, 1996.

COLES, E. H. **Patologia Clínica Veterinária**, 3ed. São Paulo:Editora Manole, 1984, p.566.

GÜRTLER, H.; KETZ, A.; SCHRÖDER, L.; SEIDEL, H. **Fisiologia Veterinária**. 4.ed. Rio de Janeiro:Editora Guanabara, 1984, p.612.

MOREIRA, M. A. B.; ROCANTI, N. V.; CORRÊA, R. R.; SOUZA, M. V. M. Diagnóstico de babesiose equina por punção esplênica. In: SIMPÓSIO INTERNACIONAL DO CAVALO ATLETA, 2007, Belo Horizonte, Brasil. **Anais...** Belo Horizonte [2007] (CD-ROM).

NIZOLI, L. Q. **Alterações hematológicas e humorais de equinos expostos à infecção por *Babesia equi*, na região sul do Rio Grande do Sul**. Pelotas: Universidade Federal de Pelotas, 2005. 39p. Dissertação (Mestrado em Sanidade Animal)- Universidade Federal de Pelotas, 2005.

SOUZA, M. V. M.; MOREIRA, M. A. B.; CORRÊA, R. R.; ROCANTI, N. V. [2007]. Diagnóstico de babesiose equina por punção esplênica. **ABRAVEQ**, 2007. Available at: <www.abraveq.com.br/novo_2007/artigo_0009.html> Access on: 8/04/09.

TIZARD, I. R. Imunidade aos parasitas. In: TIZARD, I. R. **Imunologia Veterinária**. 5. ed. São Paulo:Editora Roca, 1998, p.326-340.

ZAUGG, J. L. Babesiose. In: SMITH, B. P. **Medicina Interna de Grandes Animais**, 3 ed. Barueri:Barueri, 2006, p.1051-1055.