



CASE REPORT

bsbm
brasilmedica

PROLIFERATIVE PERIOSTITIS ASSOCIATED WITH DENS IN DENTE

RAFAEL SINDEAUX,¹ ANDRÉ FERREIRA LEITE,² PAULO TADEU DE SOUZA FIGUEIREDO,² ANDRÉ LUÍS VIEIRA CORTEZ,³ DÉBORA FERREIRA CARNEIRO,⁴ ELIETE NEVES DA SILVA GUERRA⁵ AND NILCE SANTOS DE MELO⁵

ABSTRACT

Proliferative periostitis is a disease characterized for successive deposition of layers of subperiosteal bone as a response reaction to a chronic inflammatory stimulation. The affected periosteum forms several rows of reactive bone that are parallel and expand the surface of the altered bone. Dens in dente is a developmental malformation resulting from invagination of the crown before calcification has occurred. They are usually diagnosed upon routine clinical and radiographic examination. An unusual case report of a mandibular dens in dente causing proliferative periostitis is presented. The source of infection was related to dens in dente in mandibular left second premolar's crown, which had apparently communication with periodontal tissues. It was successfully treated by surgical therapy with antibiotic during the treatment. After the extraction of the affected tooth, radiographic follow-up showed the decrease of proliferative periostitis, and remodeling of the cortical bone.

Key words. Osteomyelitis; periostitis; dens in dente; radiography.

RESUMO

PERIOSTITE PROLIFERATIVA ASSOCIADA A DENS IN DENTE

A periostite proliferativa é uma doença caracterizada por sucessivas deposições de camadas de osso subperiosteal como resposta a um estímulo crônico inflamatório. O periosteio afetado forma sucessivas camadas de osso reacional paralelas entre si e expandem a superfície óssea nesse local. *Dens in dente* é uma alteração do desenvolvimento resultante de invaginação de esmalte para a dentina antes de sua calcificação ocorrer. Usualmente são diagnosticadas em exames clínicos-radiográficos de rotina. Um relato de caso clínico raro é apresentado sobre *dens in dente* na coroa do segundo pré-molar inferior causando periostite proliferativa. A fonte de infecção foi o *dens in dente* que tinha comunicação do meio bucal com a área do periodonto. Foi realizada a extração do dente anômalo associado com uso de antibióticos. As radiografias de controle mostraram diminuição da periostite proliferativa com o remodelamento do osso cortical.

Palavras-chave. Osteomielite; periostite; dens in dente e radiografia.

INTRODUCTION

Proliferative periostitis is a nonsuppurative bone reaction resulting from a continued low-grade inflammatory or infectious stimulation. It can be considered a distinctive type of chronic osteomyelitis, commonly secondary to dental infections. The terms “Garrè's osteomyelitis” and “periostitis ossificans” are not ideal to describe this entity.¹ The lesion is usually asymptomatic, although

little or moderate pain have been reported.² The radiographic image of the lesion generally shows radiopaque laminations parallel to each other and to the cortical surface of the involved bone.²⁻⁴

Dens in dente, also known as dens invaginatus, is an anomaly of development of teeth resulting from an alteration in the normal growth pattern of the dental papilla. It frequently results in early pulp necrosis and so can be associated with periapical pathosis.⁵

¹ Medical doctor, specialist in Odontologic Radiology and Imaginology. Coresponedecede: SQN 111, bloco J, ap. 602, Asa Norte, Brasília, DF. CEP 70754-100, Telephone: 61 3273 3860, e-mail: rafasindeaux@yahoo.com.br

² PhD, Health Sciences, Professor, Universidade de Brasília (UnB).

³ PhD, Bucomaxilofacial surgery and traumatology, Professor, Universidade de Brasília.

⁴ Master. Health Sciences, Professor, Universidade de Brasília.

⁵ PhD. Bucal Pathology, Professor, Universidade de Brasília.

Received in 20-8-2009. Accepted in 20-9-2009.

The purpose of this paper is to present a case of proliferative periostitis associated with an atypical dens invaginatus.

CASE REPORT

An 11-year-old caucasian boy was referred to University Hospital of Brasilia for evaluation of a hard swelling involving the left side of the mandible. Intraoral examination demonstrated a variation in the morphology and size of the mandibular left second premolar's crown. Tooth was nonresponsive to both cold and electric pulp testing, indicating a diagnosis of pulp necrosis. The gingival and oral mucosa were normal without evidence of periodontal disease (figure 1-A).

Panoramic radiograph revealed an unusual morphology of the crown. An extensive radiopaque projection was observed attached to the crown of the tooth and was probably lined by enamel, as could be presumed by the radiopacity of its surface outline (figure 1-B). In association with a anomalous tooth was an extended area of periapical radiolucency. It could be seen that the inferior mandibular cortex was expanded under the radiolucent area. Intraoral radiograph examination disclosed the presence of type C3 dens in dente according to Schulze and Brand⁶ classification (figure 1-C). A mandibular occlusal radiograph showed an "onion skin" appearance, caused by the successive deposition of layers of subperiosteal bone, with an osteolytic area associated with the tooth (figure 1-D). The diagnosis of proliferative periostitis was confirmed radiographically.

The patient was treated with clindamycin and metronidazole in order to reduce the swelling size and stop lesions development. As the first management has failed, the second management was extraction of the affected tooth (Figure 1-E). Microscopic examination of the lesion showed a localized mass of chronic inflammatory tissue, with acute and chronic inflammatory infiltrate containing macrophages, polymorphonuclear cells; plasma cells and T lymphocytes. The diagnosis of the apical granuloma was confirmed.

The extracted tooth was prepared to microscopic examination. The longitudinal cross-section of the tooth showed the invagination of the enamel extending beyond the open apex.

Upper two thirds of invagination malformations are lined with enamel, compatible with dens in dente (figure 1-F).

The follow up showed a reduction in the size of the swelling. The occlusal radiographic showed a remodeling of cortical bone. The complete repair of the cortical and tissue periapical was observed eight months later (figure 2).

DISCUSSION

This is a case of proliferative periostitis caused by dens in dente. We haven't found any association of those two entities in the literature review despite the fact that dens in dente commonly is associated with pulp necrosis and periapical lesion.

The etiological factors for proliferative periostitis include periapical and periodontal infections, untreated fractures, developing tooth follicle, unerupted teeth, previous extraction site, pericoronaritis, buccal bifurcation cyst, lateral inflammatory odontogenic cyst, and nonodontogenic infection.¹⁻⁴ In the present report, it may be suggested that it was the periapical lesion associated with the anomalous premolar that led to the development of proliferative periostitis.

In this case, an expanded form of proliferative periostitis appeared as a hemieliptical newly formed bone. The enlargement was well outlined with a thin cortical surface located on the outer of the original cortex. According to Kawai's classification, this presentation was categorized as type I-2.³

Neoperiostosis, described by Eversole et al.⁷ represents a periosteal cellular proliferation with generation of new bone that appears clinically as osseous expansion and radiographically as cortical layering, often termed 'onion skinning'. There was no biopsy performed in our case. Some authors have stated that if there is a clinical evidence of facial asymmetry with localized osseous enlargement and radiographic cortical redundancy, with a source of infection, and complete or partial repair occurs after removal of the cause, then this can be considered proliferative periostitis.⁷

Dens in dente is an anomalies of teeth development characterized by an enamel-lined channel that originates on the coronal surface and passes apically through part or all of the root and end

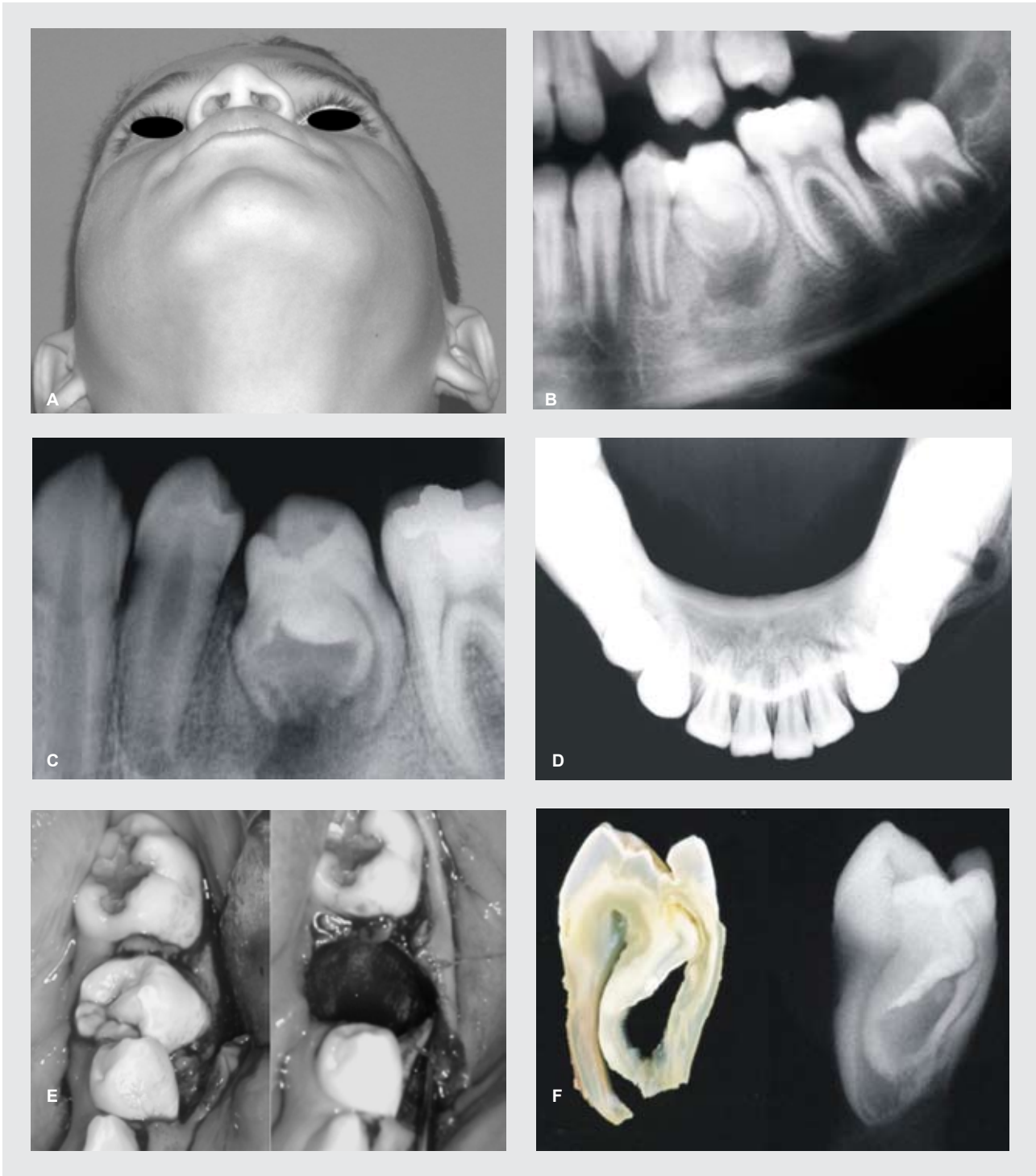

Figure 1. A – discrete swelling at the left side of the lower face; B – zoom of panoramic radiograph – Anomalous tooth in the region of the lower left second premolar associated with periapical lesion White arrow indicates periosteal bone reaction; C – preoperative periapical radiograph showing the mandibular left premolar with radicular dens invaginatus. Note incomplete dilated root with open apex and associated periapical radiolucent lesion; D – initial mandibular occlusal radiograph with low exposure exhibiting proliferative periostitis. Classic onion skin osseous buccal expansion extending from premolar and molar area. Note the osteolytic area in the new bone; E – photographs of the surgery. Beginning of extraction. It can be seen the abnormal size and morphology of the dens invaginatus. Photograph of the site of dens invaginatus extracted; F – longitudinal section of the extracted tooth shows extension of invagination beyond the open apex. Postextraction radiograph from lateral direction shows severe radicular dens invaginatus. Upper two thirds of invagination malformation are lined with enamel.

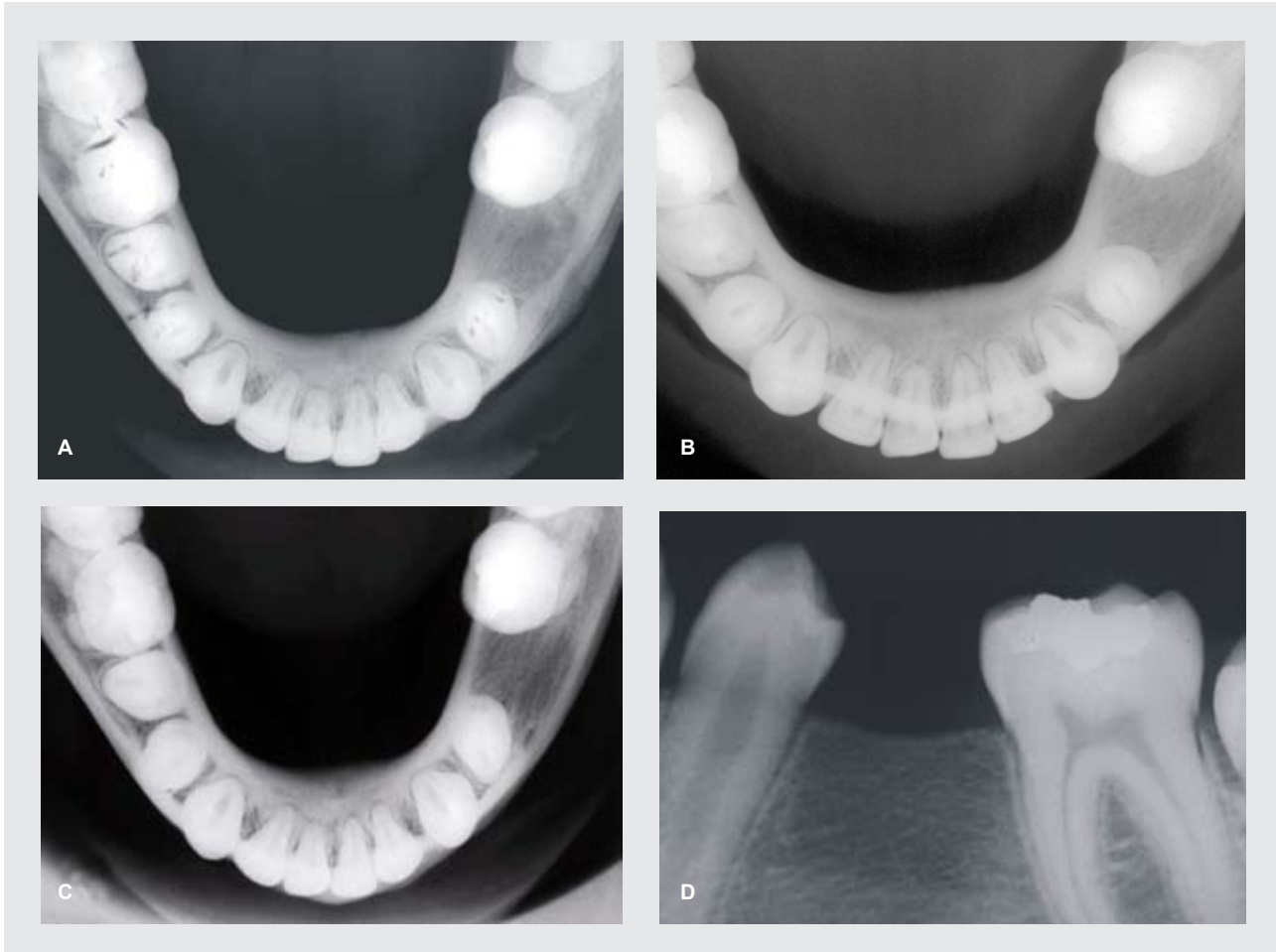


Figure 2. Resolution of proliferative periostitis and periapical lesion. A, B and C: occlusal radiographs and D periapical radiograph. A – mandibular occlusal radiograph only 2 months after tooth extraction showing reduction of periostitis; B – two months later. Notice the loss of “onion skin appearance”. Discrete swelling; C – Six months after initial examination, original contour of the left mandible is reconstructed; D – periapical radiograph six months after tooth extraction. Note the complete resolution of the periapical radiolucency.

into the periodontal ligament.⁵ Schulze and Brand⁶ proposed a classification system for dens in dente anomaly that classifies malformations with respect to morphology of the invagination as well as the anatomic crown form. In this case, the tooth was classified morphologically as type C-3.

Several theories have been proposed to clarify the origin of *dens in dente*, like a focal failure of growth of the internal enamel epithelium leading to proliferation of the surrounding normal epithelium with eventual engulfment of the static area, distortion of the enamel organ occurs during tooth development and results in protrusion of a part of the enamel organ, and others include infection, trauma and genetics as possible contributing factors.⁸

The simultaneous occurrence of proliferative periostitis with dens in dente may suggest the presence of a malformed tooth allowed the entrance of bacteria and started an inflammatory reaction. Channels may also exist between the invagination and the pulp, forming a direct communication which allows the entry of irritants and microorganisms into pulpal tissues.⁵

It was decided to extract the tooth because of the complex root canal system. Therefore, it was difficult to perform an endodontic treatment. Previously, oral antibiotic was prescribed to reduce swelling size and the infection. Once the cause was removed, the bone remodeled itself gradually.

In general, proliferative periostitis in young people is curable when early diagnosis is made



and adequate treatment is performed. However, if the correct diagnosis is delayed by more than 6 months, it may progress into a persistent and deforming stage.⁴

The literature shows that some authors had used computed tomography to help the diagnosis of proliferative periostitis.^{1,2} As in our report, in the majority of cases plain radiographs give us enough information not only in the initial assessment of dental anomalies, such as dens in dente, and proliferative periostitis, but also after treatment and follow-up. This is particularly relevant to developing countries such as Brazil, where other imaging modalities of diagnosis are not always available.

It is important to understand the mechanism responsible for periosteal reaction. In some patients, inflammatory processes in the vicinity of the skeleton lead to an uncoupled remodeling process, in which more bone is formed than resorbed. Thus, inflammatory processes secrete factors or elements that influence both osteoblasts and osteoclasts, but is the relative proportions of these activities that will determine whether bone loss or enhanced bone formation will develop. In inflammation-induced bone remodeling, the activities of osteoblasts and osteoclasts are influenced not only by signaling molecules from immune cells, but also by systemic hormones, including sex hormones. Evidence has been presented indicating that prostaglandins, as with parathyroid hormones are able to stimulate not only bone resorption but also bone formation. One potential stimulator of inflammation-induced bone formation could be prostaglandin E2.⁹⁻¹⁰

In conclusion, an abnormality of development of teeth can allow the entry of bacteria and result in periapical lesions. In this case, this persistent low-grade infection caused a response of the periosteal tissue known as proliferative periostitis. The proliferative periostitis is unusual because its development depends on the occurrence of a set of critically integrated conditions: that is a chronic infection in a young individual with a periosteum capable of vigorous osteoblastic activity and a equilibrium between the virulence of the infectious agents and the host resistance.¹¹

The elimination of source of infection leads to completely resolution of the process that might be observed in radiographic follow-up. The early diagnosis is important in order to avoid progress in a persistent stage. Plain radiographs examination generally provides valuable information in the early detection of the disease.

CONFLICTS OF INTERESTS

None declared.

REFERENCES

1. Tong AC, Ng IO, Yeung KM. Osteomyelitis with proliferative periostitis: an unusual case. *Oral Surg Oral Med Oral Pathol Oral Radiol Endod.* 2006;102:e14-e9.
2. Belli E, Matteini C, Andreano T. Sclerosing osteomyelitis of Garre periostitis ossificans. *J Craniofac Surg.* 2002;13:765-8.
3. Kawai T, Murakami S, Sakuda M, Fuchihata H. Radiographic investigation of mandibular periostitis ossificans in 55 cases. *Oral Surg Oral Med Oral Pathol Oral Radiol Endod.* 1996;82:704-12.
4. Kannan SK, Sandhya G, Selvarani R. Periostitis ossificans (Garre's osteomyelitis) radiographic study of two cases. *Int J Paediatr Dent.* 2006;16:59-64.
5. Mupparapu M, Singer SR. A rare presentation of dens invaginatus in a mandibular lateral incisor occurring concurrently with bilateral maxillary dens invaginatus: case report and review of literature. *Aust Dent J.* 2004;49:90-3.
6. Schulze C, Brand E. Dens invaginatus (dens in dente). *ZWR.* 1972;81:653-60.
7. Eversole LR, Leider AS, Corwin JO, Karian BK. Proliferative periostitis of Garre: its differentiation from other neoperiostoses. *J Oral Surg.* 1979;37:725-31.
8. Er K, Kustarcl A, Özan U, Tasdemir T. Nonsurgical endodontic treatment of dens invaginatus in a mandibular premolar with large periradicular lesion: A case report. *J Endod.* 2007;33:322-4.
9. Lerner UH. Inflammation-induced bone remodeling in periodontal disease and the influence of post-menopausal osteoporosis. *J Dent Res.* 2006;85:596-607.
10. Hosdman AB, Bauer BC, Dempster DW, Dian L, Hanley DA, Harris ST, et al. Parathyroid hormone and teriparatide for the treatment of osteoporosis: a review of the evidence and suggested guidelines for its use. *Endocr Rev.* 2005;26:688-703.
11. Felsberg GJ, Gore RL, Schweitzer ME, Jui V. Sclerosing osteomyelitis of Garrè (periostitis ossificans). *Oral Surg Oral Med Oral Pathol.* 1990;70:117-20.